



JOURNAL OF ZANKOY SULAIMANI

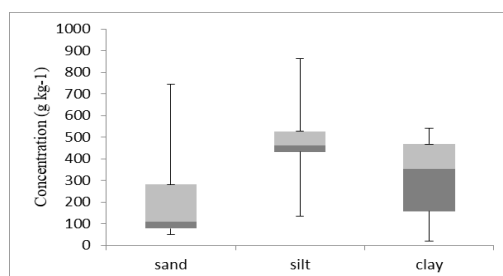
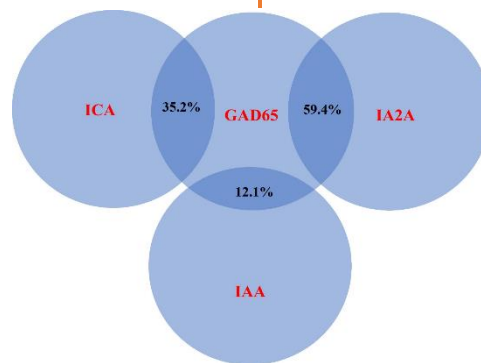
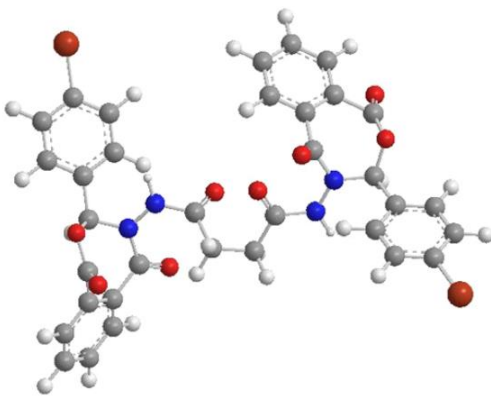
Part -A- (Pure and Applied Sciences)

VOLUME 25 ISSUE 2 December 2023

ISSN: 1812-4100

www.jzs.univsul.edu.iq

AUTHOR'S COPY





Detection of *Cystoisospora belli* among Children in Sulaimaniyah, Iraq

Fatimah Mohammed Ali^{1*}

1 Nursing Department, Sulaimani Technical Institute, Sulaimani Polytechnic University, Sulaimani, Kurdistan Region, Iraq

*Corresponding email: fatimah.ali@spu.edu.iq

Article info	Abstract
Original: 202320/08/ Revised: 01/10/2023 Accepted: 08/10/2023 Published online: 20/12/2023 Keywords: <i>Cystoisospora belli</i> , <i>coccidian parasite</i> , <i>children diarrhoea</i> , <i>cross-sectional study</i>	<p>Background: <i>Cystoisospora belli</i> inhabits epithelial cells of the upper part of human small intestine, producing resistant oocysts that are infrequently detected in stool specimens but can spread and cause infection. Objectives: To determine the rate of <i>C. belli</i> infection among children and correlate the rate of infection with the patient's variables. Patients and Methods: In this cross-sectional study, 156 fresh stool samples were collected from children suffering from diarrhea or abdominal discomfort in Dr Jamal Ahmed Rashid Pediatric Teaching Hospital, Sulaimaniyah, Iraq, from July to August 2021. Slides for direct wet mount and fixed smears stained with modified Ziehl-Neelson stain were prepared for each sample. Additionally, the correlation between the parasitic infection rate and patients' variables (age, gender, residency, duration of infection, and type of drinking water/stool) was determined. Results: None examined stool samples were positive for <i>C. belli</i> oocyst by direct wet mount technique, while the modified ZN staining method revealed 42 (26.92%) positive samples. The highest rate of <i>C. belli</i> infection (15.38%) was found among children aged 4-6 years ($p=0.000$), male patients (15.38%), patients who lived in an urban area (23.08%) ($p\geq 0.05$), had infection for 1-3 days (15.38%) ($p=0.038$), used bottle water (15.38%) ($p=0.02$), and patients had liquid/semiliquid stool type (11.54%) ($p=0.485$). On the other hand, modified ZN stain showed coinfections with other protozoa, including <i>Cryptosporidium spp.</i>, <i>Microsporidia spp.</i>, <i>Cyclospora spp.</i> and <i>Blastocystis hominins</i> at rates of 10.26%, 5.13%, 3.85% and 1.28%, respectively. Conclusions: There was a relatively high rate of <i>C. belli</i> infection among children in Sulaimaniyah, Iraq, despite other types of protozoa.</p>

Introduction

Coccidian parasites, including *Cystoisospora belli* are among the causes of intestinal protozoan infection in humans and animals and their primary symptoms include diarrhea, which might be bloody in severe cases. However, most coccidian infections are asymptomatic, but young or immunocompromised patients may suffer from severe symptoms and death [1].

C. belli, previously known as *Isospora belli*, is a apicomplexan coccidian, unicellular protozoa that parasitizes the upper small intestine of humans and causes diarrhea [2]. Infection with this parasite is cosmopolitan in distribution but more common in tropical/subtropical climates, the Middle East, and areas with poor sanitation [3]. It is associated with outbreaks of diarrhea in mental wards and daycare centres [4].

Also, studies shown that *C. belli* does not require an intermediate host and it can be transmitted directly from person to person through the ingestion of sporulated oocysts from contaminated water and food [5]. After the invasion of the small intestinal epithelial cells and completes its life cycle within the cytoplasm of the enterocytes, oocysts (diagnostic stage) are excreted with the feces and develop outside the host into mature

cysts [6]. Additionally, *C. belli* can also be found in the large intestine, lymphatic nodes, the spleen, the liver and even in blood smears [7].

Most infections are asymptomatic, and symptomatic cystoisosporiasis (acute and chronic) is characterized by watery diarrhea, colicky abdominal pain, vomiting, dehydration, malabsorption, weight loss, and peripheral eosinophilia. Infection is typically self-limited in immunocompetent hosts, but chronic and severe illnesses in infants, young children, and healthy adults have been reported [2].

The diagnosis of *C. belli* relies on direct or concentrated wet smears of fresh or preserved stool specimens that must be repeated because of the intermittent shedding of its cysts in stools. The acid-fast stain is another detection method by which the oocyst is stained red [7]. A real-time polymerase chain reaction (PCR) assay targeting the internal transcribed spacer 2 region of the ribosomal RNA gene was developed for the detection of *C. belli* DNA in fecal samples [8].

C. belli considers itself an opportunistic pathogen; however, it causes severe clinical conditions under immunosuppression, especially human immunodeficiency virus (HIV) patients [9]. Thus, this study aimed to determine the infection rate of *C. belli* among children with diarrhea and abdominal discomfort in Sulaimaniyah, Iraq for the first time.

Materials and Methods

Study setting

This cross-sectional study was conducted on fresh stool samples of 156 children with diarrhoea or abdominal discomfort at Dr. Jamal Ahmed Rashid Pediatric Teaching Hospital, Sulaimaniyah, Iraq, in July-August 2021.

Questionnaire

A well-prepared questionnaire was used to collect patient data (including age, gender, residency, duration of infection, source of drinking water, and type of stool) from their mothers through direct interviews.

Inclusion criteria

Children aged >1-year-old with diarrhea and abdominal discomfort, regardless of gender and nationality.

Exclusion criteria

Children with chronic diseases (such as diabetes mellitus) and debilitated diseases (such as cancer) were not enrolled.

Study procedure

The collected stool specimens were placed in a clean, sterile, and well-sealed plastic container with a cover, then labelled with the date and name of the patient and transported directly into the laboratory without fixative in a cooled icebox. Next, each stool sample was examined macroscopically for consistency, colour, mucus or blood. At the same time, microscopic examinations were done based on two preparations for each stool sample.

Direct wet mount preparation

A drop of normal saline was placed on the centre of a clean slide. Then, with an applicator stick, a small portion of stool specimen was picked up, mixed with normal saline, covered with a cover slip, and examined under a microscope using the objective lens of 10×, then 40× magnification power.

Modified Ziehl-Neelson technique

A small amount of stool sample was picked up with a clean applicator stick and spread by rolling the stick over the middle part of the slide. Then, the smear was dried, fixed with 2-3 drops of absolute methanol, and let to dry. Finally, smears were stained with Modified Ziehl-Neelson (ZN) acid-fast stain to detect oocysts of *C. belli* and other coccidian parasites.

Ethical approval and consent to participate

The protocol of this study was revised and approved by the Scientific and Ethical Committee of Sulaimani Technical Institute, The patients and their parents or/and legal guardian filled out a written consent form and were informed about the purpose of the study. Also, they were allowed free to quit at any time without giving a reasonable declaration.

Statistical analysis

Statistical analysis was done using SPSS, Chicago, USA (Version 21). Frequency and percentage were calculated for all variables, and the correlations between the variables were determined using Chi-square test. A p-value of 0.05 or less was considered significant.

Results

In a total of 156 examined stool specimens, 42 (26.92%) samples were positive, and 114 (73.08%) were negative for the oocysts of *C. belli* using modified Z-N staining (Figure 1). At the same time, direct wet mount examination didn't reveal any oocyst of *C. belli*.

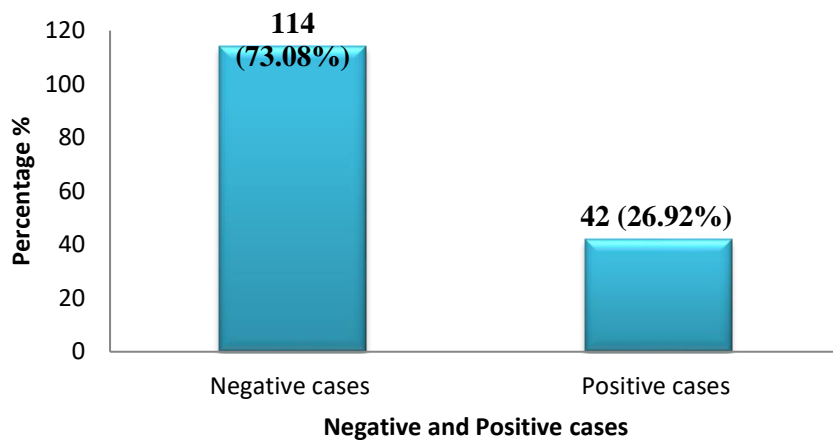


Figure 1: *Cystoisospora belli* infection rate in children using Modified Ziehl-Neelson stain.

Furthermore, microscopical examination showed the presence of other parasites, including *Entamoeba histolytica* cyst (9.0%), monilia (5.1%), cysts and trophozoites of *Giardia lamblia* (0.6%), and *Enterobius vermicularis* ova (0.6%) (Figure 2), highly significant differences.

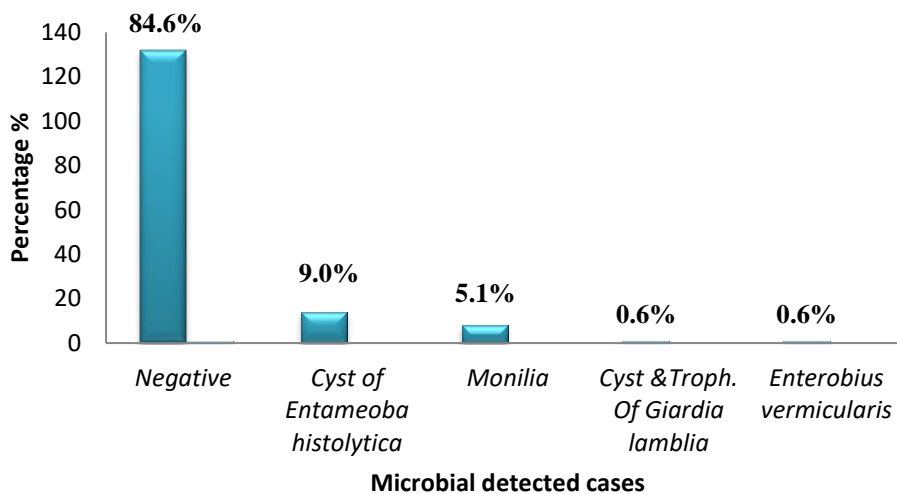


Figure 2: Microbial isolates from examined children stool samples using light microscope.

The highest rate of infection (15.38%) was found among children aged 4-6 years, followed by the age group >9 years (7.69%), and then 1-3 years (3.85%) with no infection among children aged 7-9 years. There was a significant difference between the rate of *C. belli* infection and the age groups (p=0.000). Regarding gender, a higher infection rate was recorded in males (15.38%) than in females (11.54%). Also, urban citizens reported a higher infection rate (23.08%) than rural citizens. However, there was no significant association between the rate of *C. belli* infection with both gender and residency (p≥0.05). The highest rate of *C. belli* was reported among those infected within 1-3 days (15.38%), followed by 4-6 days (7.69%), then 7-9 days (3.85%) with no detected protozoa in patients >9 days being ill. Significant differences existed between the infection rate and illness duration (p=0.038). The current study found a higher rate (15.38%) of disease among children who consume bottled water, followed by tap water (11.54%), and no infection among those who drank tap/bottled water. Also, significant differences between the disease rate and the drinking water type were observed (p=0.02). Furthermore, the same infection rate (11.54%) was observed in both liquid and semiliquid stools. The formed stool was reported at 3.85%, with no significant association between the infection rate and patient chair types (Table 1).

Table 1: The correlation between *Cystoisospora belli* infection and the patients' variable.

Variable	No. of sample	<i>C. belli</i> detection using ZN test		P-value	
		Negative	Positive		
		Number, %			
Age (Year)	1-3	62 (39.7)	56 (35.9)	6 (3.85)	0.0 00**
	4-6	64 (41.0)	40 (25.64)	24 (15.38)	
	7-9	10 (6.4)	10 (6.41)	0 (0.00)	
	>9	20 (12.8)	8 (5.13)	12 (7.69)	
Gender	Male	76 (48.7)	52 (33.33)	24 (15.38)	0.2 01
	Female	80 (51.3)	62 (39.740)	18 (11.54)	
Residency	Urban	139 (89.1)	103 (66.03)	36 (23.08)	0.4 1
	Rural	17 (10.9)	11 (7.05)	6 (3.85)	
Duration of Infection (Day)	1-3	107(68.6)	83 (53.21)	24 (15.38)	0.0 38*
	4-6	27 (17.3)	15 (9.62)	12 (7.69)	
	7-9	16 (10.3)	10 (6.41)	6 (3.85)	
	> 9	6 (3.8)	6 (3.85)	0.0 (0.0)	
Type of Drinking water	Tap water	88 (56.4)	70 (44.87)	18 (11.54)	0.0 2*
	Bottle water	57 (36.5)	33 (21.15)	24 (15.38)	
	Tap & bottle	11 (7.05)	11 (7.05)	0 (0.0)	
Type of stool	Formed	18 (11.5)	12 (7.69)	6 (3.85)	0.4 85
	Semiliquid	79 (50.6)	61 (39.10)	18 (11.54)	
	Liquid	59 (37.8)	41 (26.28)	18 (11.54)	

*: Significant difference, **: Highly significant difference using Chi-square test, ZN: Ziehl-Neelsen acid-fast stain

Moreover, modified ZN stain revealed the presence of other protozoa, including *Cryptosporidium spp.*, *Microsporidia*, *Cyclospora spp.*, and *Blastocystis hominins* accounting for 10.26%, 5.13%, 3.85%, 1.28%, respectively (Figure 3).

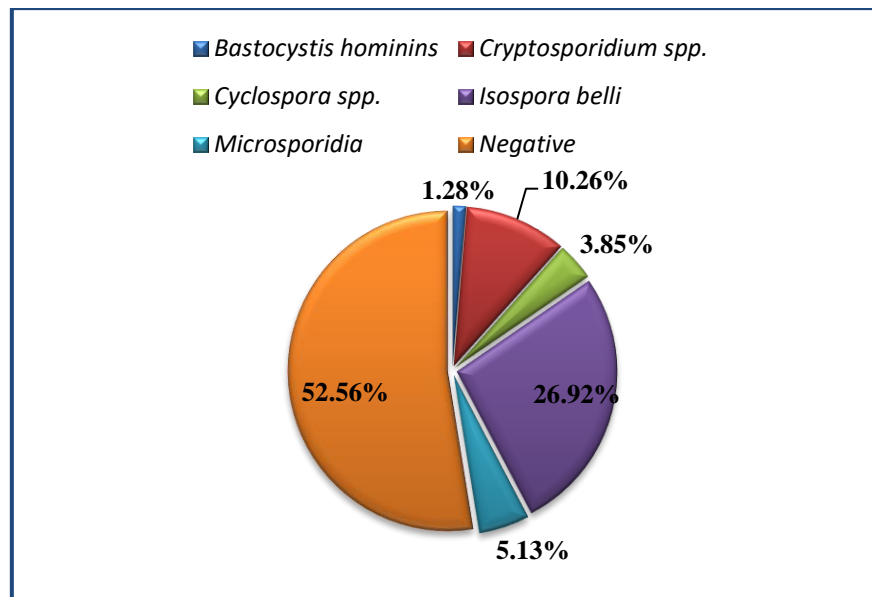


Figure 3: Identified parasites in stool samples of children using modified Ziehl-Neelsen stain.

Discussion

Cystoisospora belli is an intestinal protozoon distributed worldwide; however, it is a less common cause of protozoal diarrhea than *Toxoplasma* and *Cryptosporidium* [10].

Many parasitic infections are prevalent and endemic in Iraq, including Sulaimaniyah, but because of limitation of research on *C. belli* infections in Iraq, with no reported data in Sulaimaniyah, this study aimed to detect it.

The direct wet mount technique was used in this study. Still, it didn't reveal any oocyst of *C. belli* in the examined stool samples of the children, which might be related to the transparent appearance of the oocysts that could be overlooked in direct faecal smears. Diagnosis can be challenging owing to intermittent and low-grade shedding of oocysts that may not be found despite actual infection [11]. However, a modified ZN stain detected a high burden of Cystoisosporiasis (26.92%) in children. This outcome is inconsistent with that found by Abdel-Hafeez et al., 2012 in Egypt (9.7%) [12], Vouking et al., 2014 in Cameroon (10.08%), Barcelos et al., 2018 in Brazil (3.8%), Al-Saeed et al., 2019 in Erbil, Iraq (3.8%) [13], Kumar et al., 2017 in India (2%) [14], and Mbae et al., 2013 in Kenya (1.2%)[15]. However, it is in line with that found by Casmo et al., 2018 in Mozambique (25%), but it is lower than that observed by Swathirajan et al., 2017 in India (88.8%) [16]. These variations were referred to the differences in the study area and designs, methods of diagnosis, the season of studies and geographic location and patient populations.

Additionally, microscopical examination in this study showed the presence of other microbial agents rather than *C. belli*, such as *Entamoeba histolytica*, monilia, *Giardia lamblia*, and *Enterobius vermicularis*. Similarly, other studies found various microbial agents, including *Giardia lamblia* [13], *Ascaris lumbricoides*, *Entamoeba histolytica*, *Trichuris trichiura*, *Giardia intestinalis*, *Hymenolepis nana*, and *Schistosoma mansoni* [17]. At the same time, the most common protozoan infection in immunosuppressed children was *Cryptosporidium parvum* (60.2%), *Blastocystis hominins* (12.1%), *Cyclospora caytenensis* (7.8%), *Entamoeba histolytica* (24.6%), and *Giardia lamblia* (17.6%) [12].

In the current study, age (4-6 years), duration of infection (1-3 days), and type of drinking water (bottled water) ($p < 0.05$) were considered as the main predisposing and risk factors for development and progression of cystoisosporiasis in diarrheal children and on the other hand, gender, residency, and type of the school had

no impact on the development and progression of the disease in children with diarrhoea. Thus, other risk factors for developing intestinal parasites were reported in other studies, such as high waste disposal habits, open field defecation, drinking water sources, and hand washing habit before meals [18].

Cryptosporidium spp., *Cyclospora spp.*, *Toxoplasma spp.*, and *C. belli* are related taxonomically [3]. Thus, the modified ZN stain revealed the presence of other protozoa, including *Cryptosporidium spp.*, *Microsporidia*, *Cyclospora spp.*, and *Blastocystis hominins*. In this regard, *Cryptosporidium spp* was detected in 34.3% and *C. belli* in 1.5% of patients with HIV/AIDS in South Ethiopia [19]. In comparison, another study reported *Cryptosporidium parvum* (43.6%), *C. belli* (15.5%) and *Blastocystis hominis* (10.5%) in HIV/AIDS patients in North West Ethiopia [20]. Moreover, Adamu et al., 2006 in Addis Ababa found emerging opportunistic parasites in diarrhoeal children, including *Cryptosporidium parvum* (8.1%), *C. belli* (2.3%), *Enterocytozoon bienewisi/Encephalitozoon intestinalis* (0.5%), *Ascaris lumbricoides* (0.5%), *Trichuris trichiura* (0.9%), *Giardia lamblia* (6.3%), *Entamoeba histolytica/ E. dispar* (1.4%), *Blastocystis hominis* (5.9%) and *Hymenolepis nana* (0.5%) [21].

Conclusions

This study concludes that there was a relatively high rate of *C. belli* infection among children in our locality. At the same time, other microbial agents, including protozoa, parasites, and fungi, were also detected. In addition, age, type of drinking water, and duration of infection significantly correlated with the protozoal rate. However, limitations of the study include lack of funding and using traditional non-quantitative techniques for *C. belli* detection. Thus, it is recommended to conduct more investigations using more advanced diagnostic methods to detect *C. belli* oocysts from stool samples.

Acknowledgements

The author would like to express her heartfelt thanks to all the healthcare and physician of Dr. Jamal Ahmed Rashid Pediatric Teaching Hospital, Sulaimaniyah, Iraq.

Conflict of interest

The authors confirm that they are not affiliated with or involved in any organization or entity with financial interests.

References

- 1.Badparva E, Kheirandish F, Ebrahimzade F. (2014). Prevalence of intestinal parasites in Lorestan Province, West of Iran. *Asian Pacific Journal of Tropical Disease* 4:S728-S732.
- 2.Putaporntip C, Jongwutiwes S. (2017). *Cystoisospora belli*. *Laboratory Models for Foodborne Infections*: CRC Press; p. 599-615.
- 3.LEE RLM. (2020). Protozoa: Phylum Apicomplexa (Malaria, Coccidian, Babesia). *Markell & Voge's Medical Parasitology-10th Sea Ed*:103.
- 4.Dubey J, Almeria S. (2019). *Cystoisospora belli* infections in humans: the past 100 years. *Parasitology* 146(12):1490-1527.
- 5.Velásquez JN, Etchart CB, Astudillo OG, et al. (2022). *Cystoisospora belli*, liver disease and hypothesis on the life cycle. *Parasitology Research* 121(1):403-411.
- 6.Dubey J, Evason KJ, Walther Z. (2019). Endogenous development of *Cystoisospora belli* in intestinal and biliary epithelium of humans. *Parasitology* 146(7):865-872.
- 7.Blohm M, Hahn A, Hagen RM, et al. (2021). Comparison of two real-time PCR assays targeting ribosomal sequences for the identification of *Cystoisospora belli* in human stool samples. *Pathogens* 10(8):1053.

8. ten Hove R-J, van Lieshout L, Brienen EA, et al. (2008). Real-time polymerase chain reaction for detection of *Isospora belli* in stool samples. *Diagnostic Microbiology and Infectious Disease* 61(3):280-283.
9. Lai KK, Goyne HE, Hernandez-Gonzalo D, et al. (2016). *Cystoisospora belli* infection of the gallbladder in immunocompetent patients. *The American Journal of Surgical Pathology* 40(8):1070-1074.
10. Li J, Wang Z, Karim MR, et al. (2020). Detection of human intestinal protozoan parasites in vegetables and fruits: a review. *Parasites & Vectors* 13:1-19.
11. Estevez EG, Levine JA. (1985). Examination of preserved stool specimens for parasites: lack of value of the direct wet mount. *Journal of Clinical Microbiology* 22(4):666-667.
12. Abdel-Hafeez EH, Ahmad AK, Ali BA, et al. (2012). Opportunistic parasites among immunosuppressed children in Minia District, Egypt. *The Korean Journal of Parasitology* 50(1):57-62.
13. Al-Saeed W, Abdullah H. (2019). Incidence of *Isospora belli* in Leukemic Children in Erbil City. *Journal of Bacteriology and Parasitology* 10(4):361-363.
14. Kumar P, Vats O, Kumar D, et al. (2017). Coccidian intestinal parasites among immunocompetent children presenting with diarrhea: Are we missing them? *Tropical Parasitology* 7(1):37-40.
15. Mbae CK, Nokes DJ, Mulinge E, et al. (2013). Intestinal parasitic infections in children presenting with diarrhoea in outpatient and inpatient settings in an informal settlement of Nairobi, Kenya. *BMC Infectious Diseases* 13(1):1-11.
16. Swathirajan CR, Vignesh R, Pradeep A, et al. (2017). Occurrence of enteric parasitic infections among HIV-infected individuals and its relation to CD4 T-cell counts with a special emphasis on coccidian parasites at a tertiary care centre in South India. *Indian Journal of Medical Microbiology* 35(1):37-40.
17. Sitotaw B, Shiferaw W. (2020). Prevalence of intestinal parasitic infections and associated risk factors among the first-cycle primary schoolchildren in Sasiga District, Southwest Ethiopia. *Journal of Parasitology Research* 2020:1-10.
18. Tegen D, Damtie D. (2021). Prevalence and Risk Factors Associated with Intestinal Parasitic Infection among Primary School Children in Dera District, Northwest Ethiopia. *Canadian Journal of Infectious Diseases and Medical Microbiology*. 2021:15.
19. Girma M, Teshome W, Petros B, et al. (2014). Cryptosporidiosis and Isosporiasis among HIV-positive individuals in south Ethiopia: a cross sectional study. *BMC Infectious Diseases* 14(1):1-6.
20. Alemu A, Shiferaw Y, Getnet G, et al. (2011). Opportunistic and other intestinal parasites among HIV/AIDS patients attending Gambi higher clinic in Bahir Dar city, North West Ethiopia. *Asian Pacific Journal of Tropical Medicine* 4(8):661-665.
21. Adamu H, Endeshaw T, Teka T, et al. (2006). The prevalence of intestinal parasites in paediatric diarrhoeal and non-diarrhoeal patients in Addis Ababa hospitals, with special emphasis on opportunistic parasitic infections and with insight into the demographic and socio-economic factors. *Ethiopian Journal of Health Development* 20(1):39-46.